

# Alterations of Interneurons of the Gerbil Hippocampus after Transient Cerebral Ischemia: Effect of Pitavastatin

Toshiki Himeda<sup>1</sup>, Natsumi Hayakawa<sup>1</sup>, Hiroko Tounai<sup>1</sup>, Mio Sakuma<sup>1</sup>, Hiroyuki Kato<sup>2</sup> and Tsutomu Araki<sup>\*1</sup>

<sup>1</sup>Department of Drug Metabolism and Therapeutics, Graduate School and Faculty of Pharmaceutical Sciences, The University of Tokushima, Tokushima, Japan; <sup>2</sup>Department of Neurology, Organized Center of Clinical Medicine, International University of Health and Welfare, Tochigi, Japan

We investigated the immunohistochemical alterations of parvalbumin (PV)-expressing interneurons in the hippocampus after transient cerebral ischemia in gerbils in comparison with neuronal nitric oxide synthase (nNOS)-expressing interneurons. We also examined the effect of 3-hydroxy-3-methylglutaryl-coenzyme A reductase inhibitor pitavastatin against the damage of neurons and interneurons in the hippocampus after cerebral ischemia. Severe neuronal damage was observed in the hippocampal CA1 pyramidal neurons 5 and 14 days after ischemia. The PV immunoreactivity was unchanged up to 2 days after ischemia. At 5 and 14 days after ischemia, in contrast, a conspicuous reduction of PV immunoreactivity was observed in interneurons of the hippocampal CA1 sector. Furthermore, a significant decrease of PV immunoreactivity was found in interneurons of the hippocampal CA3 sector. No damage of nNOS-immunopositive interneurons was detected in the gerbil hippocampus up to 1 day after ischemia. Thereafter, a decrease of nNOS immunoreactive interneurons was found in the hippocampal CA1 sector up to 14 days after ischemia. Pitavastatin significantly prevented the neuronal cell loss in the hippocampal CA1 sector 5 days after ischemia. Our immunohistochemical study also showed that pitavastatin prevented significant decrease of PV- and nNOS-positive interneurons in the hippocampus after ischemia. Double-labeled immunostainings showed that PV immunoreactivity was not found in nNOS-immunopositive interneurons of the brain. The present study demonstrates that cerebral ischemia can cause a loss of both PV- and nNOS-immunoreactive interneurons in the hippocampal CA1 sector. Our findings also show that the damage to nNOS-immunopositive interneurons may precede the neuronal cell loss in the hippocampal CA1 sector after ischemia and nNOS-positive interneurons may play some role in the pathogenesis of cerebral ischemic diseases. Furthermore, our present study indicates that pitavastatin can prevent the damage of interneurons in the hippocampus after cerebral ischemia. Thus, our study provides valuable information for the pathogenesis after cerebral ischemia.

*Neuropsychopharmacology* (2005) **30**, 2014–2025. doi:10.1038/sj.npp.1300798; published online 22 June 2005

**Keywords:** interneurons; HMG-CoA reductase; immunohistochemistry; parvalbumin; nNOS; gerbil

## INTRODUCTION

Selective vulnerability of neurons in the central nervous system (CNS) to a brief period of transient cerebral ischemia is a well-known phenomenon that is particularly evidence in the hippocampus (Kirino, 1982; Pulsinelli *et al*, 1982; Araki *et al*, 1992, 1993). The pyramidal neurons in the hippocampal CA1 sector begin to degenerate a few days after ischemia. In contrast, interneurons of the hippocampal CA1 sector and granule cells of dentate gyrus are resistant to

such a brief period of ischemic insult (Nitsch *et al*, 1989; Tortosa and Ferrer, 1993). A similar pattern is seen in the human hippocampus after cerebral ischemia (Petito *et al*, 1987). A previous study has demonstrated that nonpyramidal neurons, like interneurons, in the hippocampal CA1 sector, can survive transient ischemia, but undergo degenerative changes following complete loss of CA1 pyramidal neurons (Fukuda *et al*, 1993). This observation suggests that interneurons are not resistant to prolonged periods of cerebral ischemia. Therefore, the postischemic changes of interneurons in the hippocampal CA1 sector which is most vulnerable to ischemia are not fully understood.

Calcium-binding proteins such as parvalbumin (PV) are thought to protect neurons against cytotoxic calcium overload because of their potential buffering ability (Tortosa and Ferrer, 1993; Ferrer *et al*, 1998). Parvalbumin is a cytosolic calcium buffer expressed in GABAergic ( $\gamma$ -aminobutyrate) interneurons and is present numerous

\*Correspondence: Professor T. Araki, Department of Drug Metabolism and Therapeutics, Graduate School and Faculty of Pharmaceutical Sciences, The University of Tokushima, 1-78, Shomachi, Tokushima 770-8505, Japan. Tel: +81 88 633 7277, Fax: +81 88 633 9511, E-mail: tsuaraki@ph.tokushima-u.ac.jp

Received 8 February 2005; revised 12 April 2005; accepted 28 April 2005

Online publication: 11 May 2005 at <http://www.acnp.org/citations/Npp051005050079/default.pdf>

nuclei of the brain (Andressen *et al*, 1993; Hontanilla *et al*, 1998). Therefore, it is well known that PV is a superior marker for a subpopulation of GABAergic interneurons (Celio, 1986).

A previous study suggests that 3-hydroxy-3-methylglutaryl-coenzyme A (HMG-CoA) reductase inhibitors decrease cerebral ischemia and infarct size in normocholesterolemic mice (Endres *et al*, 1998). A recent interesting study suggests that HMG-CoA reductase inhibitor inhibits the formation of TNF- $\alpha$  and peroxynitrite in activated microglia, thereby protecting dopaminergic neurons from inflammatory damage (Selley, 2005). Pitavastatin (NK-104) is a novel synthetic potent and selective inhibitor of HMG-CoA reductase, the rate-limiting enzyme in cholesterol biosynthesis (Aoki *et al*, 1997). This compound is known to lower plasma total cholesterol levels and reduce triglyceride levels (Kajinami *et al*, 2000). We recently reported that pitavastatin can protect against the hippocampal CA1 neuronal damage after transient cerebral ischemia in gerbils (Kumagai *et al*, 2004; Muramatsu *et al*, 2004). These observations indicate that the HMG-CoA reductase inhibitor pitavastatin is effective against transient cerebral ischemia. However, little is known about the effect of pitavastatin against changes of interneurons in the hippocampal CA1 sector after transient cerebral ischemia.

In the present study, therefore, we investigated the immunohistochemical alterations of PV-positive interneurons in the hippocampus after 5 min of transient cerebral ischemia in gerbils in comparison with neuronal nitric oxide (NO) synthase (nNOS)-positive cells, which are limited to interneurons in the hippocampus. We also examined the effect of HMG-CoA reductase inhibitor pitavastatin against the changes of interneurons in the hippocampal CA1 sector after cerebral ischemia.

## MATERIALS AND METHODS

### Experimental Animals

Male adult Mongolian gerbils, weighing 60–90 g (Nihon SLC Co., Shizuoka, Japan), were used. The animals were housed in a controlled environment ( $23 \pm 1^\circ\text{C}$ ,  $50 \pm 5\%$  humidity) and were allowed food and tap water *ad libitum*. The room lights were on between 0800 and 2000 h. The animals were anesthetized with 2% halothane in a mixture of 30% oxygen and 70% nitrous oxides. Bilateral carotid arteries were exposed and anesthesia was discontinued to minimize its effect. The carotid arteries were clamped with aneurysmal clips for 5 min, and then the animals were allowed to survive for 1 h ( $n=6$ ), 5 h ( $n=5$ ), 1 day ( $n=5$ ), 2 days ( $n=5$ ), 5 days ( $n=8$ ), and 14 days ( $n=5$ ) after ischemia. Sham-operated animals ( $n=7$ ) were treated in the same manner, except for the clipping of the bilateral carotid arteries. Body temperature was maintained at  $37\text{--}38^\circ\text{C}$  with a heating pad equipped with a thermostat until the animals started moving. All experiments were performed in accordance with the Guidelines for Animal Experiments of the Tokushima University School of Medicine.

### Drug Treatments

To evaluate the neuroprotective effect of drug treatment, pitavastatin at doses of 3, 10, or 30 mg/kg was administrated

orally twice a day for 5 days before transient cerebral ischemia. Transient cerebral ischemia was induced in gerbils 1 h after the last treatment with pitavastatin. Vehicle (0.5% carboxymethylcellulose (CMC)) was also administered in sham-operated gerbils under the same conditions. Pitavastatin was generously provided by Kowa company, Ltd, Tokyo, Japan.

### Immunohistochemistry

The animals were anesthetized with sodium pentobarbital (50 mg/kg, i.p.) 1, 5 h, 1, 2, 5, and 14 days after cerebral ischemia, and the brains were perfusion-fixed with 4% paraformaldehyde in 0.1 M phosphate buffer (pH 7.4) following a heparinized saline flush. The brains were removed 1 h after perfusion fixation at  $4^\circ\text{C}$  and were immersed in the same fixative until they were embedded in paraffin. Paraffin sections, 5  $\mu\text{m}$  in thickness, were stained with cresyl violet and used for immunohistochemistry.

For immunohistochemical studies, a Vectastain elite ABC kit (Vector Labs., Burlingame, CA, USA), mouse anti-PV monoclonal antibody (Chemicon International, Inc., Temecula, CA, USA), and rabbit anti-nNOS polyclonal antibody (Zymed Labs., San Francisco, CA, USA) were used. The immunohistochemical staining with anti-PV antibody (1:500) and anti-nNOS antibody (1:500) was performed as described previously (Kurosaki *et al*, 2002; Muramatsu *et al*, 2002). Negative control sections were treated in the same way, except that each antibody was omitted. Immunoreactions for PV and nNOS staining were visualized using Vector DAB (3',3'-diaminobenzidine) substrate kit (Vector Labs., Burlingame, CA, USA) and Vector NovaRed substrate kit (Vector Labs., Burlingame, CA, USA).

The immunostaining for PV and nNOS was semiquantitatively graded as intense (grade 3), moderate (grade 2), weak (grade 1), and not detectable (grade 0), without the examiner knowing the experimental protocols, as described previously (Kato *et al*, 1995; Muramatsu *et al*, 2003; Kurosaki *et al*, 2005). Values were expressed means  $\pm$  SD. Statistical significance was evaluated using the nonparametric Dunnett's multiple comparison test.

Double-labeled immunostaining with anti-PV and anti-nNOS antibodies was performed in some sections of gerbils. The immunohistochemical staining with anti-NOS antibody was performed as described above. Then, the double-labeled immunostaining with anti-PV antibody was performed as described above. Immunoreactions for PV and nNOS staining were visualized using Vector DAB substrate kit (brown) and Vector NovaRed substrate kit (red), respectively.

## RESULTS

### Neuronal Loss in the Hippocampus after Transient Cerebral Ischemia

Neuronal death in CA1 pyramidal cells after ischemia was elucidated by cresyl violet staining. In the hippocampus, sham-operated gerbils showed no neuronal damage throughout the experiments. Gerbils subjected to ischemia showed no neuronal damage in the hippocampus up to 2 days after ischemia. At 5 and 14 days after ischemia, severe

neuronal damage was observed in the hippocampal CA1 pyramidal neurons. However, the neuronal damage was not seen in the hippocampal CA3 sector and dentate gyrus. Prophylactic treatment with pitavastatin significantly prevented the neuronal cell loss in the hippocampal CA1 sector 5 days after ischemia, as shown in Figures 1 and 2.

### PV Staining in the Hippocampus after Transient Cerebral Ischemia

Representative microphotographs of PV staining in the hippocampus are shown in Figures 3 and 4. In sham-operated gerbils, PV-immunoreactive interneurons were clearly evident in the hippocampus. The majority of PV-immunoreactive cell bodies with varicose dendrites were located to the hippocampus. In animals subjected to ischemia, the PV immunoreactivity was unchanged up to 2 days after ischemia. At 5 and 14 days after ischemia, in contrast, a conspicuous reduction of PV immunoreactivity was noted in interneurons of the hippocampal CA1 sector. Furthermore, a significant decrease of PV immunoreactivity was found in interneurons of the hippocampal CA3 sector. However, dentate gyrus showed no significant changes throughout the experiments. In contrast, prophylactic treatment with pitavastatin significantly prevented a loss of PV-immunoreactive interneurons in the hippocampal CA1 sector 5 days after ischemia, as shown in Tables 1 and 2. However, prophylactic treatment with pitavastatin did not prevent the reduction of PV-immunoreactive interneurons in the hippocampal CA3 sector. Furthermore, this compound showed no significant changes of PV-immunoreactive cells in dentate gyrus 5 days after ischemia.

### nNOS Staining in the Hippocampus after Transient Cerebral Ischemia

Representative microphotographs of nNOS staining in the hippocampus are shown in Figures 5 and 6. nNOS immunoreactivity was observed in interneurons of the hippocampus in sham-operated gerbils. No damage of nNOS-immunopositive interneurons was detected in the gerbil hippocampus up to 1 day after transient forebrain ischemia. Thereafter, a decrease of nNOS immunoreactivity was found in the hippocampal CA1 sector 2, 5, and 14 days after ischemia. In the hippocampal CA3 sector, nNOS immunoreactivity decreased only 5 days after ischemia. In contrast, the changes of nNOS immunoreactivity were not observed in the granule cells throughout the experiments, except for a transient decrease in this region 2 days after ischemia. Prophylactic treatment with pitavastatin significantly prevented a loss of nNOS-immunoreactive interneurons in the hippocampal CA1 and CA3 sector 5 days after ischemia. Furthermore, this compound showed no significant changes of nNOS-immunoreactive cells in the dentate gyrus 5 days after ischemia, as shown in Tables 1 and 2.

### Double-Labeled Immunostainings

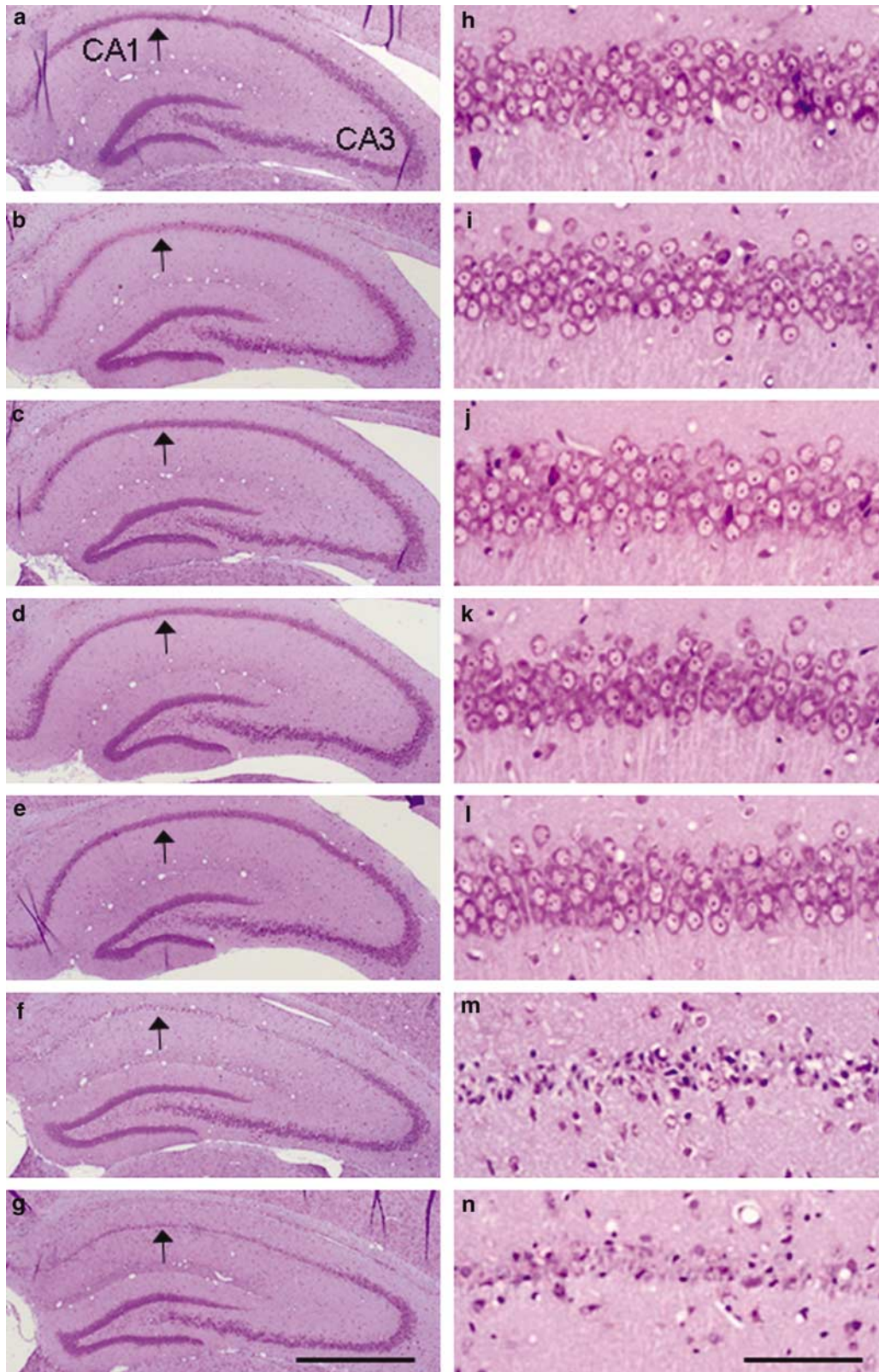
Representative microphotographs of double-labeled immunostainings with anti-PV and anti-nNOS antibody are shown in Figure 7. PV immunoreactivity was not found in

nNOS-immunopositive interneurons of the hippocampus and cerebral cortex. Thus, the interneuron with PV was different from that with nNOS.

## DISCUSSION

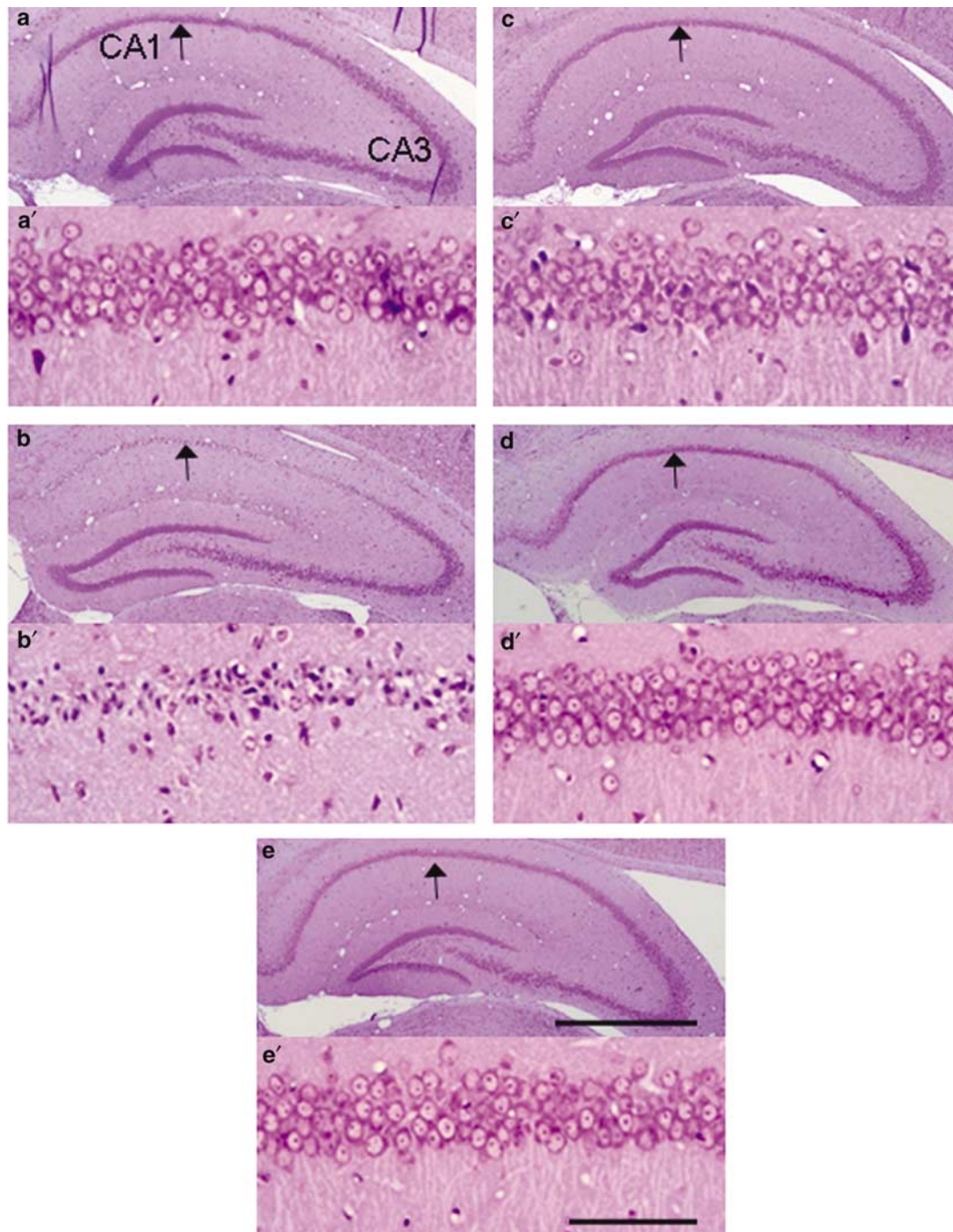
It is well known that calcium plays a key role in ischemic neuronal damage (Paschen, 1996). Calcium-binding proteins belonging to the EF-hand family function as high-affinity, selective intracellular calcium buffers. One of these calcium-binding proteins, PV, is present throughout the brain, where it is selectively localized in a subpopulation of GABA-containing neurons (Heizmann, 1984; Celio, 1986). Therefore, the PV has been regarded as a superior marker for a subpopulation of GABAergic interneurons throughout the brain (Celio, 1986; Schwartz-Bloom and Sah, 2001). A previous study has shown that PV-immunoreactive neurons are particularly resistant to transient ischemic insult which produces hippocampal CA1 neuronal death (Nitsch *et al*, 1989). Furthermore, Tortosa and Ferrer (1993) also demonstrated that PV-immunoreactive neurons in the hippocampus are preserved after a brief period of cerebral ischemia in gerbils. For this reason, it is suggested that the calcium-buffering properties of PV protect the GABAergic neurons from ischemic cell damage. PV-containing neurons also exhibit a higher survival rate in the human epileptic hippocampus (Sloviter *et al*, 1991), and, recently, a protective effect of PV on excitotoxic motor neurons death has been observed (Van Den Bosch *et al*, 2002). On the other hand, other studies suggest that PV-immunoreactive neurons were gradually depleted in the brain of gerbils after a longer period of ischemia (Fukuda *et al*, 1993). Furthermore, PV-containing neurons are supposed to be selectively vulnerable in Alzheimer's disease (Solodkin *et al*, 1996) and not to be protected in some forms of epilepsy (Bouilleret *et al*, 2000). Thus, much evidence for the vulnerability and role of PV-containing neurons to stress response such as ischemia and epilepsy is contradictory.

Increasing evidence demonstrates that NO participates in the mechanisms of cerebral ischemia and much attention has been focused on the role of NO in the pathogenesis of ischemic brain damage. Excessive production of NO, and consequent increase of the oxygen-free radical peroxynitrite, has been implicated in neuronal cell loss occurring both in acute and chronic brain pathologies (Dawson and Dawson, 1995; Iadecola, 1997; Yun *et al*, 1997). However, the precise role of NO in the pathogenesis of ischemic brain damage is not fully understood (Choi, 1993; Iadecola *et al*, 1994). NO, a free radical gas, synthesized from L-arginine by NOS is involved in a wide range of physiological and pathological mechanisms, including the control of the cardiovascular, immune, and nervous systems, as well as cellular neurotoxicity (Dawson *et al*, 1991; Moncada *et al*, 1991; Dawson and Snyder, 1994). Three isoforms of NOS enzymes are traditionally recognized: nNOS, inducible NOS (iNOS), and endothelial NOS (eNOS). Among the three isoforms of NOS enzymes, nNOS is the main NOS isoform in the brain, as its catalytic activity and proteins are identifiable throughout the CNS (Bredt *et al*, 1991; Huang *et al*, 1993). It is known that nNOS is restricted to occasional



**Figure 1** Representative photographs with Cresyl violet staining in the hippocampus (a–g) and CA1 sector (h–n) after transient cerebral ischemia. (a, h): sham-operated gerbil brain. (b, i): vehicle-treated gerbil brain 1 h after ischemia. (c, j): vehicle-treated gerbil brain 5 h after ischemia. (d, k): vehicle-treated gerbil brain 1 day after ischemia. (e, l): vehicle-treated gerbil brain 2 days after ischemia. (f, m): vehicle-treated gerbil brain 5 days after ischemia. (g, n): vehicle-treated gerbil brain 14 days after ischemia. Arrows show location of changes. Each group contained 5–8 animals. Bar (a–g) = 1 mm. Bar (h–n) = 100  $\mu$ m.



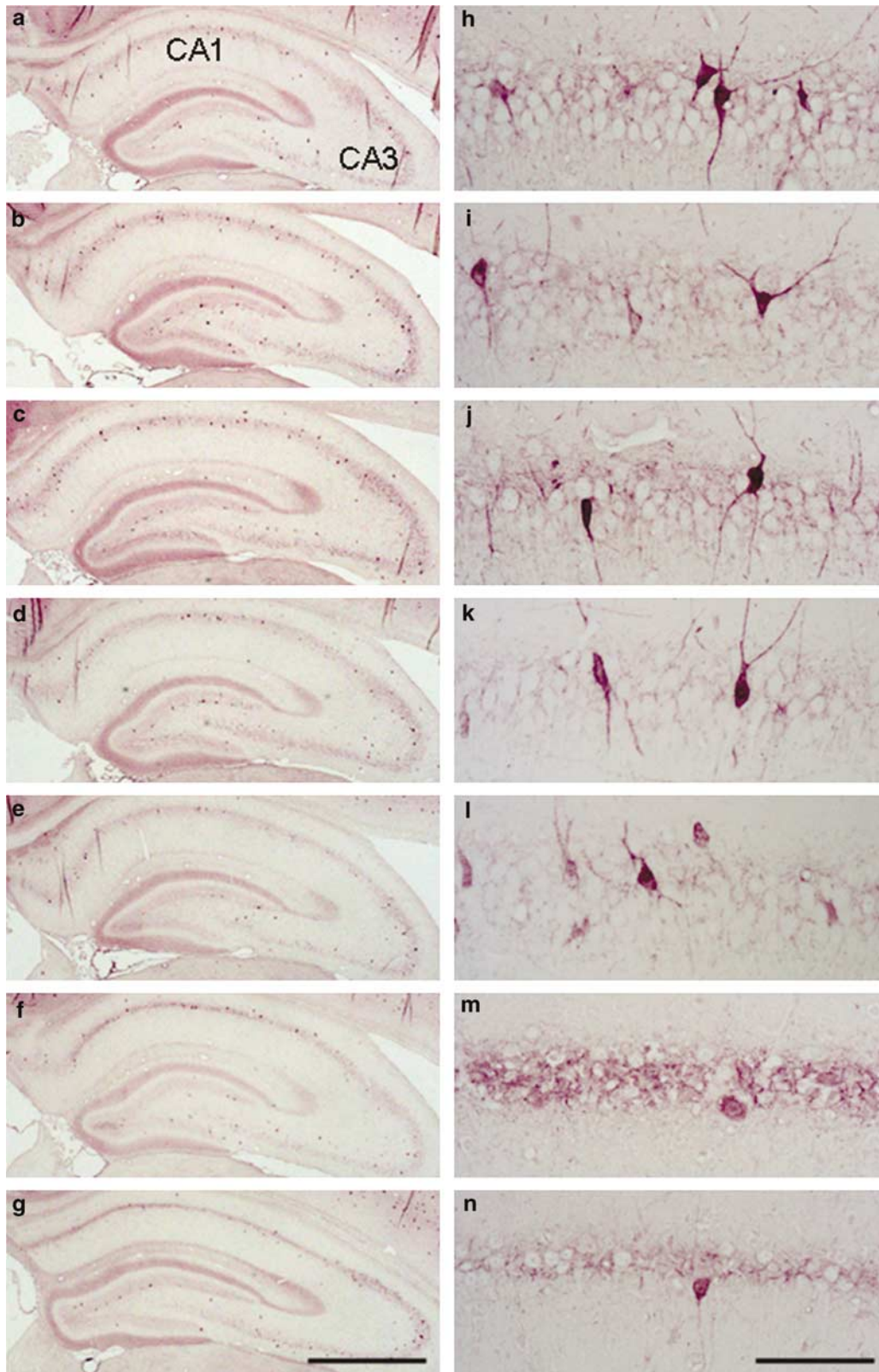


**Figure 2** Effect of pitavastatin on neuronal densities in the CA1 sector (a'–e') of the hippocampus (a–e) of the gerbil brain 5 days after transient cerebral ischemia. (a, a'): sham-operated gerbil brain. (b, b'): vehicle-treated gerbil brain 5 days after ischemia. (c, c'): pitavastatin (3 mg/kg)-treated gerbil brain 5 days after ischemia. (d, d'): pitavastatin (10 mg/kg)-treated gerbil brain 5 days after ischemia. (e, e'): pitavastatin (30 mg/kg)-treated gerbil brain 5 days after ischemia. Arrows show location of changes. Each group contained 7–8 animals. Bar (a–e) = 1 mm. Bar (a'–e') = 100  $\mu$ m.

interneurons in the hippocampus (Dinerman *et al*, 1994). In the mouse striatum, furthermore, nNOS-positive cells are known to be interneurons (Zucker *et al*, 2005). However, little is known about the exact changes of nNOS expression as interneurons in the hippocampus after transient cerebral ischemia in gerbils.

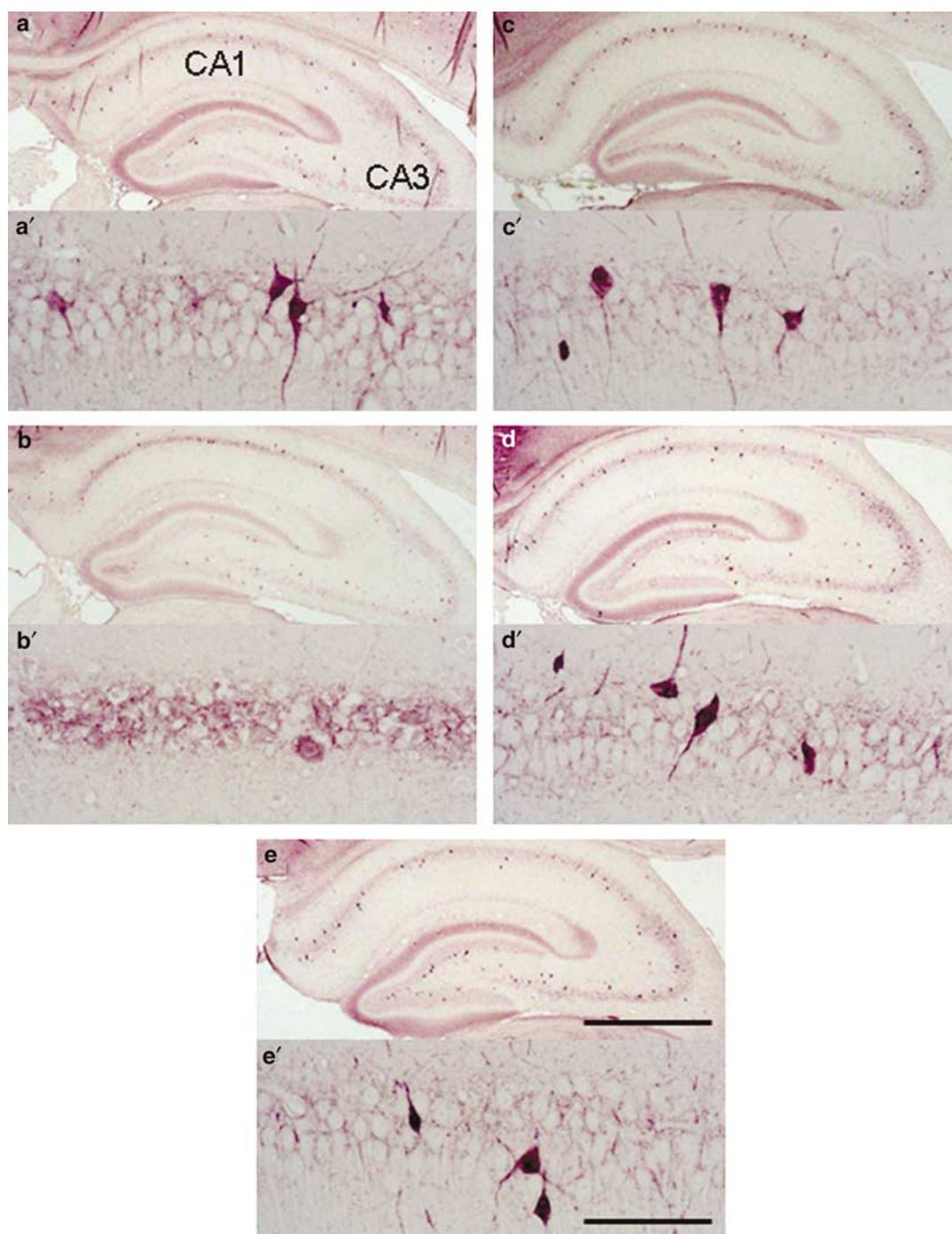
In the present study, no neuronal damage in the hippocampus was observed up to 2 days after transient

cerebral ischemia. At 5 and 14 days after ischemia, severe neuronal damage was found only in the hippocampal CA1 sector. The PV immunoreactivity was also unchanged up to 2 days after ischemia. At 5 and 14 days after ischemia, however, a conspicuous reduction of PV immunoreactivity was noted in interneurons of the hippocampal CA1 sector. Furthermore, a significant decrease of PV immunoreactivity was found in interneurons of the hippocampal CA3 sector.



**Figure 3** Representative photomicrographs with PV immunostaining of the hippocampus (a–g) and CA1 sector (h–n) after transient cerebral ischemia. (a, h): sham-operated gerbil brain. (b, i): vehicle-treated gerbil brain 1 h after ischemia. (c, j): vehicle-treated gerbil brain 5 h after ischemia. (d, k): vehicle-treated gerbil brain 1 day after ischemia. (e, l): vehicle-treated gerbil brain 2 days after ischemia. (f, m): vehicle-treated gerbil brain 5 days after ischemia. (g, n): vehicle-treated gerbil brain 14 days after ischemia. Each group contained 5–8 animals. Bar (a–g) = 1 mm. Bar (h–n) = 100  $\mu$ m.





**Figure 4** Effect of pitavastatin on PV immunoreactivity in the CA1 sector (a'–e') of the hippocampus (a–e) of the gerbil brain 5 days after transient cerebral ischemia. (a, a'): sham-operated gerbil brain. (b, b'): vehicle-treated gerbil brain 5 days after ischemia. (c, c'): pitavastatin (3 mg/kg)-treated gerbil brain 5 days after ischemia. (d, d'): pitavastatin (10 mg/kg)-treated gerbil brain 5 days after ischemia. (e, e'): pitavastatin (30 mg/kg)-treated gerbil brain 5 days after ischemia. Each group contained 7–8 animals. Bar (a–e) = 1 mm. Bar (a'–e') = 100  $\mu$ m.

However, the dentate gyrus showed no significant changes throughout the experiments. On the other hand, no damage of nNOS-immunopositive interneurons was detected in the gerbil hippocampus up to 1 day after transient cerebral ischemia. Thereafter, a decrease of nNOS immunoreactivity was found in the hippocampal CA1 sector at 2, 5, and 14 days after ischemia. In the hippocampal CA3 sector, nNOS immunoreactivity decreased only 5 days after ischemia. In

contrast, the changes of nNOS immunoreactivity were not observed in the granule cells throughout the experiments, except for a transient decrease in this region 2 days after ischemia. These results indicate that transient cerebral ischemia can cause a loss of both PV and nNOS-immunoreactive interneurons in the hippocampal CA1 sector. Furthermore, our findings suggest that the damage to nNOS-immunopositive interneurons may precede the

**Table 1** Time Course of Parvalbumin and nNOS Immunoreactivity in the Gerbil Hippocampus after Transient Cerebral Ischemia

	CA1 sector	CA3 sector	Dentate gyrus
<i>Parvalbumin</i>			
Sham	2.0±0.3	2.3±0.4	1.8±0.4
1 h	2.0±0.6	2.2±0.5	1.8±0.4
5 h	2.7±0.3	2.4±0.3	1.9±0.2
1 day	2.1±0.3	2.1±0.1	1.9±0.4
2 days	1.7±0.4	1.9±0.3	1.6±0.5
5 days	0.9±0.5*	1.4±0.3**	1.4±0.2
14 days	0.7±0.3**	1.5±0.2*	1.8±0.3
<i>nNOS</i>			
Sham	2.6±0.3	2.9±0.2	2.4±0.4
1 h	2.4±0.2	2.9±0.2	2.3±0.3
5 h	2.8±0.2	2.9±0.2	2.0±0.4
1 day	2.8±0.3	2.8±0.3	2.1±0.4
2 days	1.8±0.4*	2.5±0.4	1.7±0.5*
5 days	1.5±0.4**	2.4±0.3*	2.0±0.6
14 days	1.6±0.6*	2.6±0.5	2.4±0.4

The immunoreactivity was semiquantitatively graded as intense (grade 3), moderate (grade 2), weak (grade 1) and not detectable (grade 0). Values were expressed as mean±SD. Each group contained 5–8 animals. Statistical significance was evaluated by nonparametric Dunnett's multiple comparison test (\* $p < 0.05$ , \*\* $p < 0.01$  compared with the sham-operated control group).

**Table 2** Effect of Pitavastatin on Parvalbumin and nNOS Immunoreactivity in the Gerbil Hippocampus 5 days after Transient Cerebral Ischemia

	CA1 sector	CA3 sector	Dentate gyrus
<i>Parvalbumin</i>			
Sham	2.0±0.3**	2.3±0.4**	1.8±0.4
Ischemia+0.5% CMC	1.0±0.5	1.4±0.3	1.4±0.2
Ischemia+Pitavastatin			
Pitavastatin (3 mg/kg)	1.5±0.5	1.4±0.3	1.3±0.2
Pitavastatin (10 mg/kg)	1.8±0.6*	1.8±0.4	1.6±0.5
Pitavastatin (30 mg/kg)	1.9±0.2**	1.8±0.2	1.7±0.2
<i>nNOS</i>			
Sham	2.6±0.3**	2.9±0.2**	2.4±0.4
Ischemia+0.5% CMC	1.5±0.4	2.4±0.4	2.0±0.6
Ischemia+Pitavastatin			
Pitavastatin (3 mg/kg)	2.1±0.5	2.7±0.4	2.0±0.3
Pitavastatin (10 mg/kg)	2.4±0.4*	2.8±0.3*	2.3±0.4
Pitavastatin (30 mg/kg)	2.3±0.7*	2.8±0.2*	2.1±0.6

The immunoreactivity was semiquantitatively graded as intense (grade 3), moderate (grade 2), weak (grade 1) and not detectable (grade 0). Values were expressed as mean±SD. Each group contained 7–8 animals. Statistical significance was evaluated by nonparametric Dunnett's multiple comparison test (\* $p < 0.05$ , \*\* $p < 0.01$  compared with ischemia+0.5%CMC group).

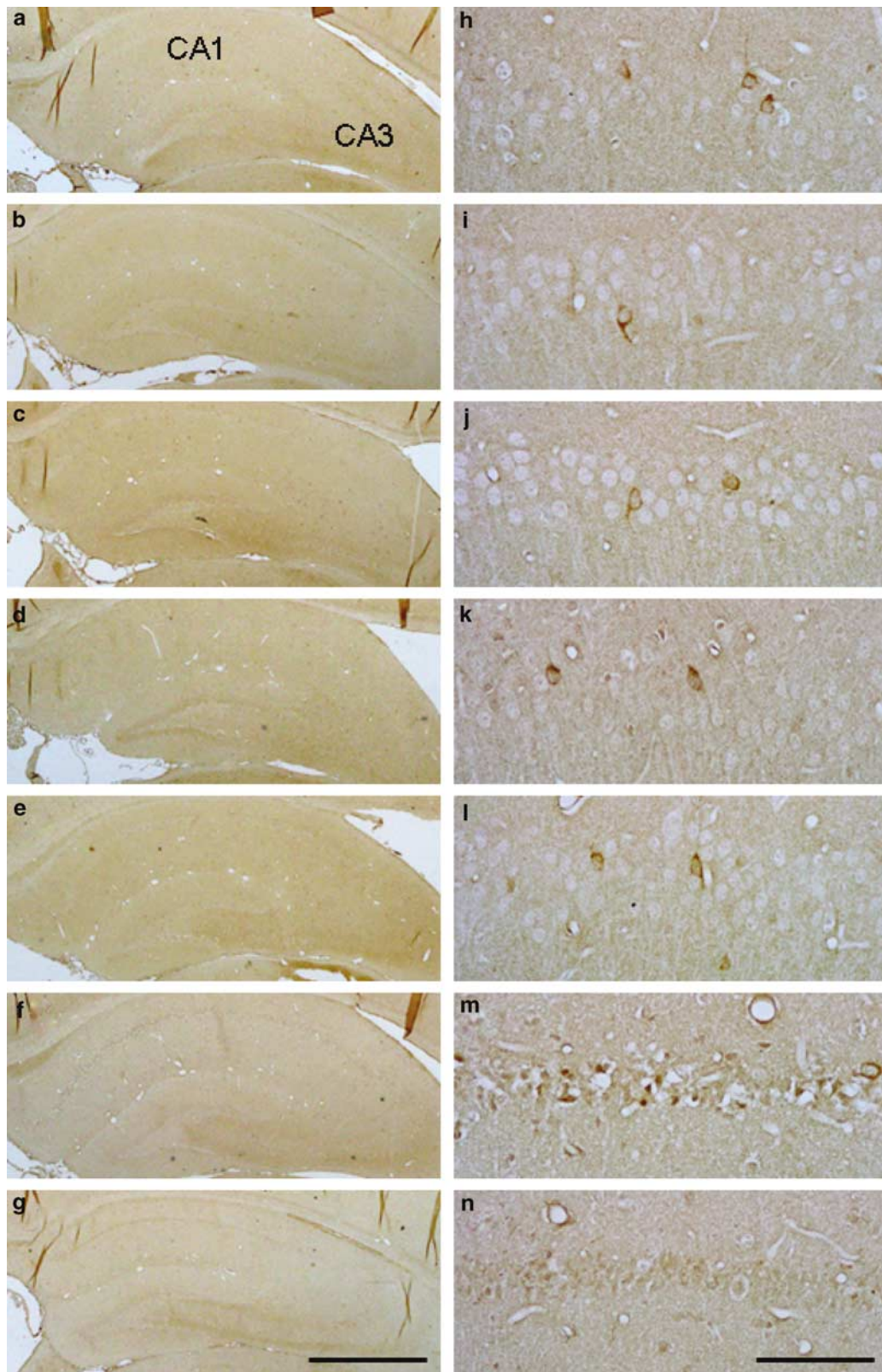
neuronal cell loss in the hippocampal CA1 sector after ischemia.

The present study with our double-labeled immunostainings demonstrates that the interneuron with PV was different from that with nNOS. nNOS has been shown to account for 95% or more of all NOS catalytic activity in the brain under basal conditions (Huang *et al*, 1993). Immunohistochemical studies have shown that 1–2% of neurons in the cortex contain NOS immunoreactivity (Bredt *et al*, 1991), later equated with neuronal isoform. These neurons constitute a relatively small subpopulation of interneurons, which also contain GABA, neuropeptide Y, and somatostatin (Vincent and Kimura, 1992; Valtchanoff *et al*, 1993). However, PV has also been regarded as a superior marker for a subpopulation of GABAergic interneurons throughout the brain (Celio, 1986). In the present study, therefore, the exact reason that PV-immunoreactive cells and nNOS-immunoreactive cells were clearly different interneurons in both cerebral cortex and hippocampal CA1 sector of gerbils is presently unclear. In this respect, a previous study demonstrated that double labeling of nNOS with calretinin or with PV did not show any double-labeled cells in the monkey cerebral cortex (Smiley *et al*, 2000). We recently reported that PV-immunoreactive cells and nNOS-immunoreactive cells were clearly different interneurons in both the striatum and substantia nigra of mice (Kurosaki *et al*, 2005). Therefore, we speculate that PV-immunoreactive interneurons and nNOS-immunoreactive interneurons may play a different role in the brain, although further studies should be performed to investigate the precise mechanism responsible for our findings.

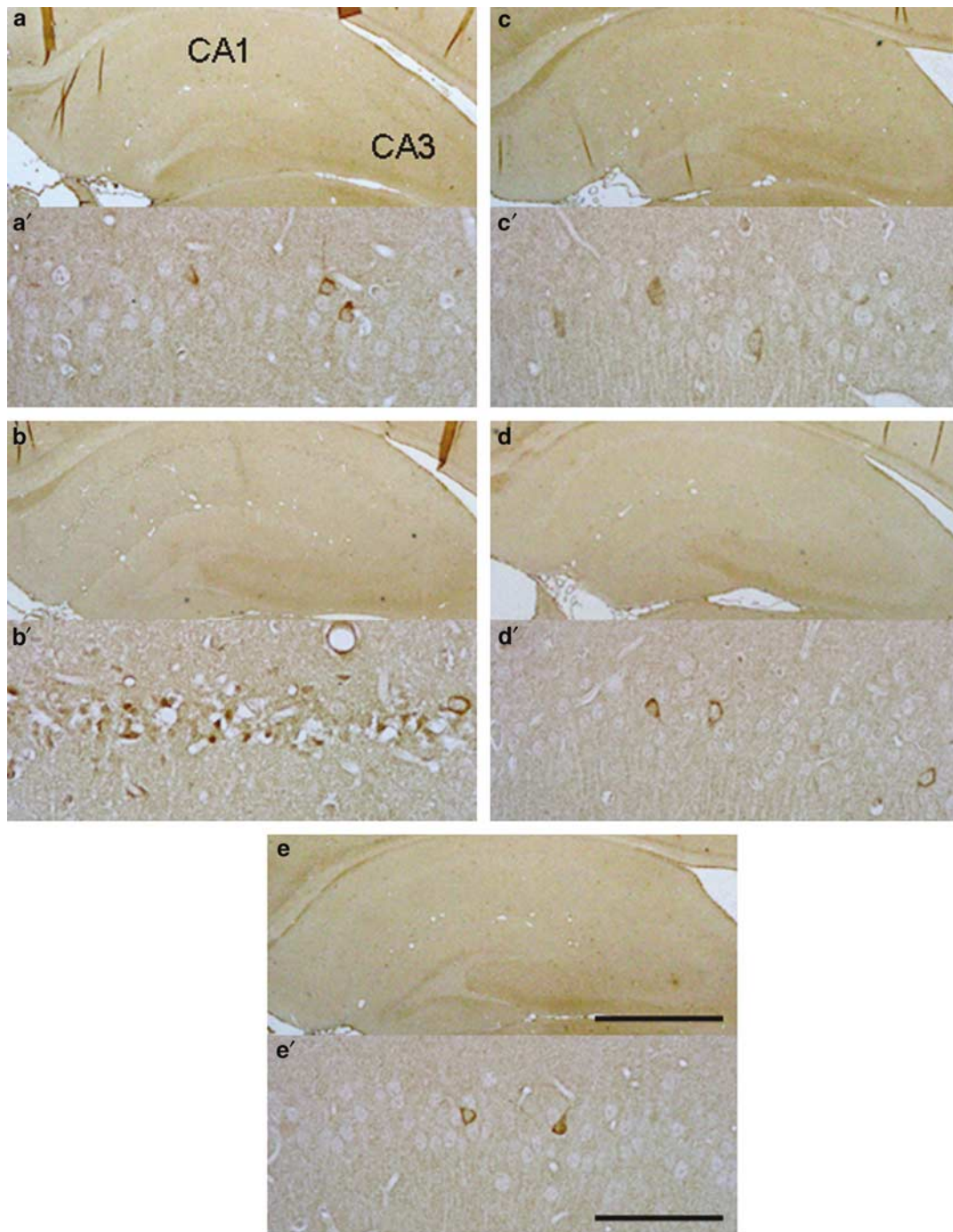
Of particular interest in the present study is that the damage to nNOS-immunopositive interneurons preceded the neuronal cell loss in the hippocampal CA1 sector after ischemia. Although the reason for this phenomenon is presently unclear, we speculate that nNOS interneurons may play some role in the pathogenesis of cerebral ischemic diseases. Furthermore, a significant loss of PV immunoreactivity and nNOS immunoreactivity was found in interneurons of the hippocampal CA3 sector. For this reason, we suggest that transient cerebral ischemia may cause the functional damage of interneurons in the hippocampal CA3 sector. However, the precise mechanisms responsible for such findings should be investigated in further studies.

Pitavastatin is a novel potent HMG-CoA reductase inhibitor with prolonged effect and has been approved for treatment of hyperlipoproteinemia (Aoki *et al*, 1997; Fujimoto *et al*, 1999). This drug is also known to lower plasma total cholesterol levels and reduce triglyceride levels. Furthermore, pitavastatin processes a 10-fold higher cholesterol-lowering effect, compared with other HMG-CoA reductase inhibitors such as pravastatin and simvastatin (Aoki *et al*, 1997; Suzuki *et al*, 1999). A recent study indicates that long-term treatment with pitavastatin is effective and safe for patients with heterozygous familial hypercholesterolemia (Noji *et al*, 2002). From these observations, it is suggested that pitavastatin is a new and potentially superior therapeutic agent in comparison with other currently available statins. Several studies suggest that HMG-CoA reductase inhibitors can affect expression of eNOS (endothelial NO synthase), increasing the bioavailability of NO (Laufs *et al*, 1997; John *et al*, 1998; Kaesemeyer





**Figure 5** Representative photomicrographs with nNOS immunostaining of the hippocampus (a–g) and CA1 sector (h–n) after transient cerebral ischemia. (a, h): sham-operated gerbil brain. (b, i): vehicle-treated gerbil brain 1 h after ischemia. (c, j): vehicle-treated gerbil brain 5 h after ischemia. (d, k): vehicle-treated gerbil brain 1 day after ischemia. (e, l): vehicle-treated gerbil brain 2 days after ischemia. (f, m): vehicle-treated gerbil brain 5 days after ischemia. (g, n): vehicle-treated gerbil brain 14 days after ischemia. Each group contained 5–8 animals. Bar (a–g) = 1 mm. Bar (h–n) = 100  $\mu$ m.



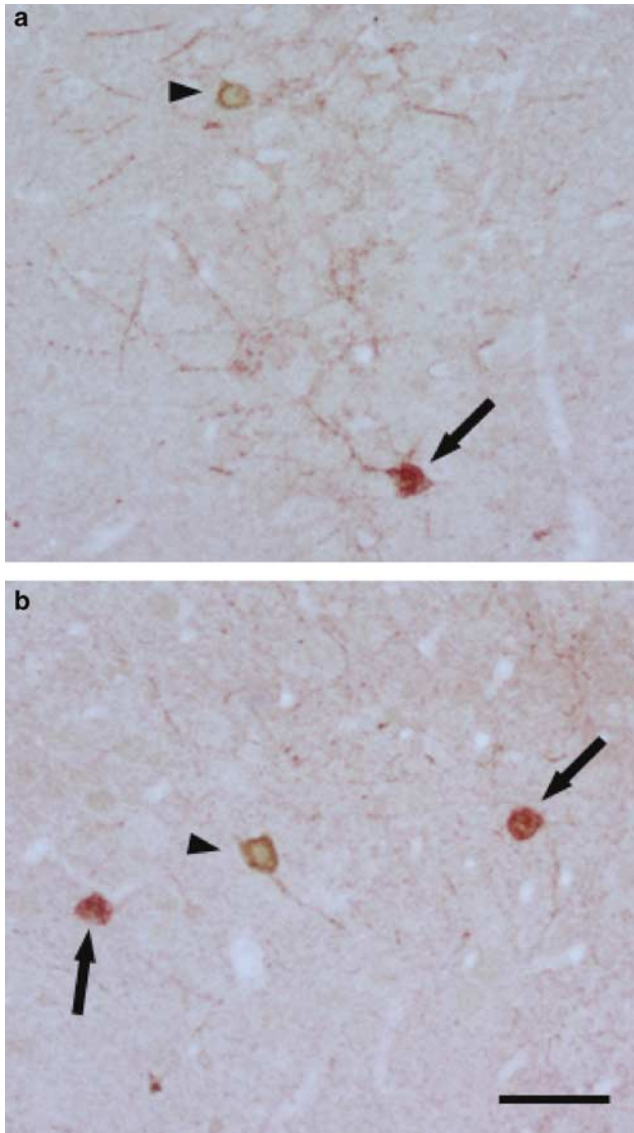
**Figure 6** Effect of pitavastatin on nNOS immunoreactivity in the CA1 sector (a'–e') of the hippocampus (a–e) of the gerbil brain 5 days after transient cerebral ischemia. (a, a'): sham-operated gerbil brain. (b, b'): vehicle-treated gerbil brain 5 days after ischemia. (c, c'): pitavastatin (3 mg/kg)-treated gerbil brain 5 days after ischemia. (d, d'): pitavastatin (10 mg/kg)-treated gerbil brain 5 days after ischemia. (e, e'): pitavastatin (30 mg/kg)-treated gerbil brain 5 days after ischemia. Each group contained 7–8 animals. Bar (a–e) = 1 mm. Bar (a'–e') = 100  $\mu$ m.

*et al*, 1999). Furthermore, a previous study demonstrates that prophylactic treatment with HMG-CoA reductase inhibitors can decrease the severity of cerebral focal ischemic damage irrespective of serum cholesterol levels (Endres *et al*, 1998). We recently reported that pitavastatin can protect against the hippocampal CA1 neuronal damage after transient cerebral ischemia in gerbils (Kumagai *et al*, 2004; Muramatsu *et al*, 2004). Based on these observations,

it is conceivable that the HMG-CoA reductase inhibitor pitavastatin are effective against transient cerebral ischemia.

The present study showed that prophylactic treatment with pitavastatin significantly prevented the neuronal death of the hippocampal CA1 sector 5 days after transient cerebral ischemia. Our immunohistochemical study also showed that pitavastatin prevented significant decrease of PV-positive interneurons and nNOS-positive interneurons





**Figure 7** Representative photomicrographs with double-labeled immunostaining with PV and nNOS of the hippocampus (a) and cerebral cortex (b) in gerbils. (Red; arrow) = PV. (Brown; arrowhead) = nNOS. Bar = 50  $\mu$ m.

in the hippocampus 5 days after ischemia. We recently reported that pitavastatin can decrease the neuronal damage of the hippocampal CA1 sector after transient cerebral ischemia in gerbils via inhibition of superoxide production (Kumagai *et al*, 2004). Therefore, the protective effect of pitavastatin against interneurons may, at least in part, be due to its free radical scavenging activity. These results suggest that HMG-CoA reductase inhibitors can protect against the damage of interneurons in the hippocampal CA1 sector after transient cerebral ischemia, although further studies are needed to investigate the exact mechanisms for our findings.

In conclusion, the present study demonstrates that transient cerebral ischemia can cause a loss of both PV and nNOS-immunoreactive interneurons in the hippocampal CA1 sector. Our findings also show that the damage to nNOS-immunopositive interneurons may precede the

neuronal cell loss in the hippocampal CA1 sector after ischemia and nNOS-positive interneurons may play some role in the pathogenesis of cerebral ischemic diseases. Furthermore, the present study suggests that transient cerebral ischemia may cause the functional damage of interneurons in the hippocampal CA3 sector. Moreover, our present study indicates that prophylactic treatment with pitavastatin can prevent the damage of interneurons in the hippocampal CA1 and CA3 sectors after transient cerebral ischemia. Thus, our study provides valuable information for the pathogenesis after transient cerebral ischemia.

## ACKNOWLEDGEMENTS

We appreciatively acknowledge Kowa Company, Ltd, Tokyo, Japan, for providing pitavastatin, and helpful advice. This study was supported in part by a Grant-in-Aid for Scientific Research (13671095 and 13670627) from the Ministry of Science and Education in Japan.

## REFERENCES

- Andressen C, Blumcke I, Celio MR (1993). Calcium-binding proteins: selective markers of nerve cells. *Cell Tissue Res* 271: 181–208.
- Aoki T, Nishimura H, Nakagawa S, Kojima J, Suzuki H, Tamaki T *et al* (1997). Pharmacological profile of a novel synthetic inhibitor of 3-hydroxy-3-methylglutaryl-coenzyme A reductase. *Arzneimittelforschung* 47: 904–909.
- Araki T, Kato H, Kanai Y, Kogure K (1993). Postischemic changes of intracellular second messengers in the gerbil brain after long-term survival: an autoradiographic study. *Neuroscience* 53: 829–836.
- Araki T, Kato H, Kogure K, Kanai Y (1992). Long-term changes in gerbil brain neurotransmitter receptors following transient cerebral ischemia. *Br J Pharmacol* 107: 437–442.
- Bouillere V, Schwaller B, Schurmans S, Celio MR, Fritschy JM (2000). Neurodegenerative and morphogenic changes in a mouse model of temporal lobe epilepsy do not depend on the expression of the calcium-binding proteins parvalbumin, calbindin, or calretinin. *Neuroscience* 97: 47–58.
- Bredt DS, Hwang PM, Glatt CE, Lowenstein C, Reed RR, Snyder SH (1991). Cloned and expressed nitric oxide synthase structurally resemble cytochrome P-450 reductase. *Nature* 351: 714–718.
- Celio MR (1986). Parvalbumin in most  $\gamma$ -aminobutyric acid-containing neurons of the rat cerebral cortex. *Science* 231: 995–997.
- Choi DW (1993). Nitric oxide: foe or friend to the injured brain? *Proc Natl Acad Sci USA* 90: 9741–9743.
- Dawson TM, Dawson VL (1995). Nitric oxide: actions and pathological roles. *Neuroscientist* 1: 7–18.
- Dawson TM, Snyder SH (1994). Gases as biological messengers: nitric oxide and carbon monoxide in the brain. *J Neurosci* 14: 5147–5159.
- Dawson VL, Dawson TM, London ED, Bredt DS, Snyder SH (1991). Nitric oxide mediates glutamate neurotoxicity in primary cortical cultures. *Proc Natl Acad Sci USA* 88: 6368–6371.
- Dinerman JL, Dawson TM, Schell MJ, Snowman A, Snyder SH (1994). Endothelial nitric oxide synthase localized to hippocampal pyramidal cells: implications for synaptic plasticity. *Proc Natl Acad Sci USA* 91: 4214–4218.
- Endres M, Laufs U, Huang Z, Nakamura T, Huang P, Moskowitz MA *et al* (1998). Stroke protection by 3-hydroxy-3-methylglutaryl (HMG)-CoA reductase inhibitors mediated by endothelial nitric oxide synthase. *Proc Natl Acad Sci USA* 95: 8880–8885.



- Ferrer I, Lopez E, Pozas E, Ballabriga J, Marti E (1998). Multiple neurotrophic signals converge in surviving CA1 neurons of the gerbil hippocampus following transient forebrain ischemia. *J Comp Neurol* 394: 416–430.
- Fujimoto H, Kojima J, Yamada Y, Kanda H, Kimata H (1999). Studies on the metabolic fate of pitavastatin, a new inhibitor of HMG-CoA reductase (4): interspecies variation in laboratory animals and humans. *Xenobiot Metabol Dispos* 14: 79–91.
- Fukuda T, Nakano S, Yoshiya I, Hashimoto PH (1993). Persistent degenerative state of non-pyramidal neurons in the CA1 region of the gerbil hippocampus following transient forebrain ischemia. *Neuroscience* 53: 23–28.
- Heizmann CW (1984). Parvalbumin, an intracellular calcium-binding protein; distribution, properties and possible roles in mammalian cells. *Experimentia* 40: 910–921.
- Hontanilla B, Parent A, de las Heras S, Gimenez-Amaya JM (1998). Distribution of calbindin D-28k and parvalbumin neurons and fibers in the rat basal ganglia. *Brain Res Bull* 47: 107–116.
- Huang PL, Dawson TM, Bredt DS, Snyder SH, Fishman MC (1993). Targeted disruption of the neuronal nitric oxide synthase gene. *Cell* 75: 1273–1286.
- Iadecola C (1997). Bright and dark sides on nitric oxide in ischemic brain injury. *Trends Neurosci* 20: 132–139.
- Iadecola C, Pelligrino DA, Moskowitz MA, Lassen NA (1994). Nitric oxide synthase inhibition and cerebrovascular regulation. *J Cereb Blood Flow Metab* 14: 175–192.
- John S, Schlaich M, Langenfeld M, Weihprecht H, Schmitz G, Weidinger G et al (1998). Increased bioavailability of nitric oxide after lipid-lowering therapy in hypercholesterolemic patients: a randomized, placebo-controlled, double-blind study. *Circulation* 98: 211–216.
- Kaesemeyer WH, Caldwell RB, Huang J, Caldwell RW (1999). Pravastatin sodium activates endothelial nitric oxide synthase independent of its cholesterol-lowering actions. *J Am Coll Cardiol* 33: 234–241.
- Kajinami K, Koizumi J, Ueda K, Miyamoto S, Takegoshi T, Mabuchi H (2000). Effects of NK-104, a new hydroxymethylglutaryl-coenzyme reductase inhibitor, on low-density lipoprotein cholesterol in heterozygous familial hypercholesterolemia. Hokuriku NK-104 Study Group. *Am J Cardiol* 85: 178–183.
- Kato H, Kogure K, Araki T, Itoyama Y (1995). Graded expression of immunomolecules on activated microglia in the hippocampus following ischemia in a rat model of ischemic tolerance. *Brain Res* 694: 85–93.
- Kirino T (1982). Delayed neuronal death in the gerbil hippocampus following ischemia. *Brain Res* 239: 57–69.
- Kumagai R, Oki C, Muramatsu Y, Kurosaki R, Kato H, Araki T (2004). Pitavastatin, a 3-hydroxy-3-methylglutaryl-coenzyme A (HMG-CoA) reductase inhibitor, reduces hippocampal damage after transient cerebral ischemia in gerbils. *J Neural Transm* 111: 1103–1120.
- Kurosaki R, Muramatsu Y, Kato H, Watanabe Y, Imai Y, Itoyama Y et al (2005). Effect of angiotensin-converting enzyme inhibitor perindopril on interneurons in MPTP-treated mice. *Eur Neuropsychopharmacol* 15: 57–67.
- Kurosaki R, Muramatsu Y, Michimata M, Matsubara M, Kato H, Imai Y et al (2002). Role of nitric oxide synthase against MPTP neurotoxicity in mice. *Neurol Res* 24: 655–662.
- Laufs U, La Fata V, Plutzky J, Liao JK (1997). Upregulation of endothelial nitric oxide synthase by HMG CoA reductase inhibitors. *Circulation* 97: 1129–1135.
- Moncada S, Palmer RM, Higgs EA (1991). Nitric oxide: physiology, pathophysiology and pharmacology. *Pharmacol Rev* 43: 109–142.
- Muramatsu Y, Kurosaki R, Kato H, Araki T (2004). Effect of pitavastatin against expression of S100 $\beta$  protein in the gerbil hippocampus after transient cerebral ischemia. *Acta Physiol Scand* 184: 95–107.
- Muramatsu Y, Kurosaki R, Mikami T, Michimata M, Matsubara M, Imai Y et al (2002). Therapeutic effect of neuronal nitric oxide synthase inhibitor (7-nitroindazole) against MPTP neurotoxicity in mice. *Metab Brain Dis* 17: 169–182.
- Muramatsu Y, Kurosaki R, Watanabe H, Michimata M, Matsubara M, Imai Y et al (2003). Expression of S100 protein is related to neuronal damage in MPTP-treated mice. *Glia* 42: 307–313.
- Nitsch C, Scotti A, Sommacal A, Kalt G (1989). GABAergic hippocampal neurons resistant to ischemia-induced neuronal death contain the Ca<sup>2+</sup>-binding protein parvalbumin. *Neurosci Lett* 105: 263–268.
- Noji Y, Higashikata T, Inazu A, Nohara A, Ueda K, Miyamoto S et al (2002). Long-term treatment with pitavastatin (NK-104), a new HMG-CoA reductase inhibitor, of patients with heterozygous familial hypercholesterolemia. *Atherosclerosis* 163: 157–164.
- Paschen W (1996). Disturbances of calcium homeostasis within the endoplasmic reticulum may contribute to the development of ischemic-cell damage. *Med Hypotheses* 47: 283–288.
- Petito CK, Feldmann E, Pulsinelli WA, Plum F (1987). Delayed hippocampal damage in humans following cardiorespiratory arrest. *Neurology* 37: 1281–1286.
- Pulsinelli WA, Brierley JB, Plum F (1982). Temporal profile of neuronal damage in a model of transient forebrain ischemia. *Ann Neurol* 11: 491–498.
- Schwartz-Bloom RD, Sah R (2001).  $\gamma$ -Aminobutyric acid<sub>A</sub> neurotransmission and cerebral ischemia. *J Neurochem* 77: 353–371.
- Selley ML (2005). Simvastatin prevents 1-methyl-4-phenyl-1,2, 3,6-tetrahydropyridine-induced striatal dopamine depletion and protein tyrosine nitration in mice. *Brain Res* 1037: 1–6.
- Sloviter RS, Sollas AL, Barbaro NM, Laxer KD (1991). Calcium-binding protein (calbindin-D28K) and parvalbumin immunocytochemistry in the normal and epileptic human hippocampus. *J Comp Neurol* 308: 381–396.
- Smiley JF, McGinnis JP, Javitt DC (2000). Nitric oxide synthase interneurons in the monkey cerebral cortex are subsets of the somatostatin, neuropeptide Y, and calbindin cells. *Brain Res* 863: 205–212.
- Solodkin A, Veldhuizen SD, Van Hoesen GW (1996). Contingent vulnerability of entorhinal parvalbumin-containing neurons in Alzheimer's disease. *J Neurosci* 16: 3311–3321.
- Suzuki H, Aoki T, Tamaki T, Sato F, Kitahara M, Saito Y (1999). Hypolipidemic effect of NK-104, a potent HMG-CoA reductase inhibitor, in guinea pigs. *Atherosclerosis* 146: 259–270.
- Tortosa A, Ferrer I (1993). Parvalbumin immunoreactivity in the hippocampus of the gerbil after transient forebrain ischemia: a qualitative and quantitative sequential study. *Neuroscience* 55: 33–43.
- Valtschanoff JG, Weinberg RJ, Kharazia VN, Schmidt HH, Nakane M, Rustioni A (1993). Neurons in rat cerebral cortex that synthesize nitric oxide: NADPH diaphorase histochemistry, NOS immunocytochemistry, and colocalization with GABA. *Neurosci Lett* 157: 157–161.
- Van Den Bosch L, Schwaller B, Vleminckx V, Meijers B, Stork S, Ruehlicke T et al (2002). Protective effect of parvalbumin on excitotoxic motor neuron death. *Exp Neurol* 174: 150–161.
- Vincent SR, Kimura H (1992). Histochemical mapping of nitric oxide synthase in the rat brain. *Neuroscience* 46: 755–784.
- Yun HY, Dawson VL, Dawson TM (1997). Nitric oxide in health and disease of the nervous system. *Mol Psychiatry* 2: 300–310.
- Zucker B, Luthi-Carter R, Kama JA, Cunah AW, Stern EA, Fox JH et al (2005). Transcriptional dysregulation in striatal projection- and interneurons in a mouse model of Huntington's disease: neuronal selectivity and potential neuroprotective role of HAP1. *Hum Mol Genet* 14: 179–189.